VisualDx 臨床診斷決策支援系統

產品介紹：

VisualDx 臨床診斷決策支援系統是一套獨特的電子資源，目前有超過 100 名各醫學領域專家參與編輯，幫助臨床醫師由使用經驗轉為以模組配對的方式進行鑑別診斷。不同於其他線上資料庫，VisualDx 依年齡、皮膚類型、身體位置和嚴重程度，可快速協助醫事人員針對疾病相關表徵差異進行鑑別，結合頂尖醫師認可的優質圖像及獨特的搜尋引擎，在短時間內提供病患專屬的個人化解答

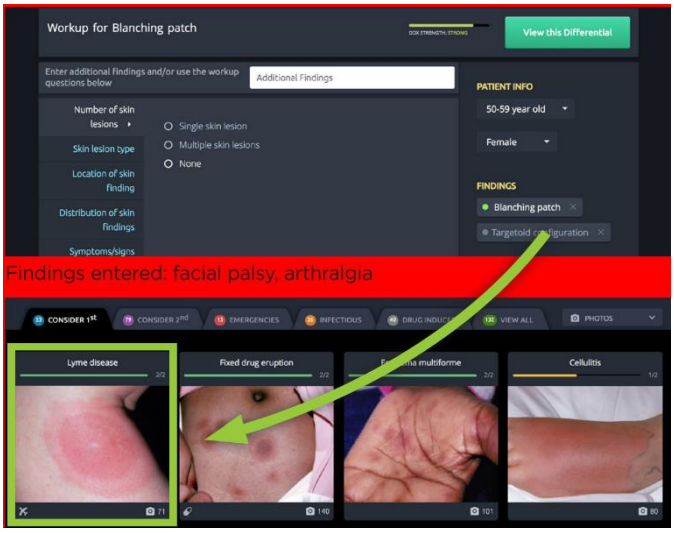

依照患部特徵進行鑑別診斷

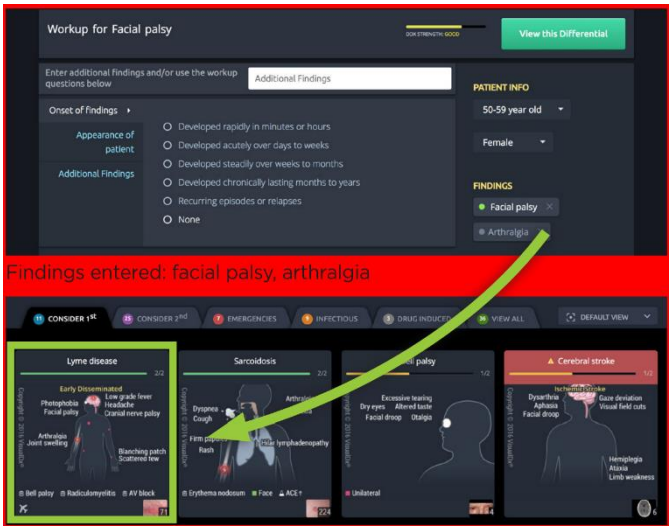

依照病患症狀進行鑑別診斷

產品特色：

- 以標準醫學術語為基礎
- 包含多種形式及變化的清晰醫學圖像
- 豐富的醫學實證資料庫
- 圖像化的搜索程序和界面
- 不斷改善和進化的機器學習系統
- 整合醫學標準術語、醫學影像、醫學實證資料、機器學習
- 提供 APP 工具，提供不限時間、地點的應用經驗

病例：

一名 40 歲女性，既往有高血壓和躁鬱症病史，數小時前開始上腹部劇烈疼痛，放射至背部，伴有噁心和嘔吐。患者否認有任何飲酒或非法藥物濫用史。最近沒有服藥紀錄，也沒有腹部外傷史。2004 年接受了膽囊切除術。體檢時，體溫正常，心跳 105 次/分鐘，血壓 132/84 mmHg。由於疼痛及嚴重的上腹壓痛，處於嚴重的痛苦中，其餘生理檢查均為正常。

A 40-year-old female with a past medical history of hypertension and bipolar disorder presented with a few hours of severe sharp epigastric abdominal pain radiating to the back associated with nausea and vomiting. The patient denied any history of consuming alcohol, or illegal drug abuse. No new medication had recently been started, and there was no history of abdominal trauma. She had had a cholecystectomy in 2004. On physical examination, she was afebrile, had a heart rate of 105 beats/min, and a blood pressure of 132/84 mm Hg. She was in severe distress due to pain with severe epigastric tenderness. The remainder of her physical exam was normal.

理學檢查顯示 WBC 為 22.1 × 10 ³ /μL，中性粒細胞為 87%，血紅素濃度為 14.0 g/dL，血小板為 380 × 10 ³ /μL。除了 2.7 mEq/L 的血鉀濃度外，其他代謝狀況並無異狀。她的懷孕檢查呈陰性，尿液藥物檢查結果正常，血清的澱粉酶為 31 IU/L（正常參考值：20-160），解脂酶為 14 IU/L（正常參考值：8-78）。

Her laboratory tests on admission revealed a WBC of 22.1 × 10^3/μL with neutrophils 87%, a hemoglobin level of 14.0 g/dL, and platelets 380 × 10^3/μL. Her comprehensive metabolic panel was unremarkable except for a potassium level of 2.7 mEq/L. She had a negative pregnancy test and a normal urine drug screen. Her serum amylase was 31 IU/L (normal ref: 20–160) and lipase was 14 IU/L (normal ref: 8–78).

CT 掃描顯示胰頭脂肪滯留，符合胰腺炎和十二指腸反應性增厚

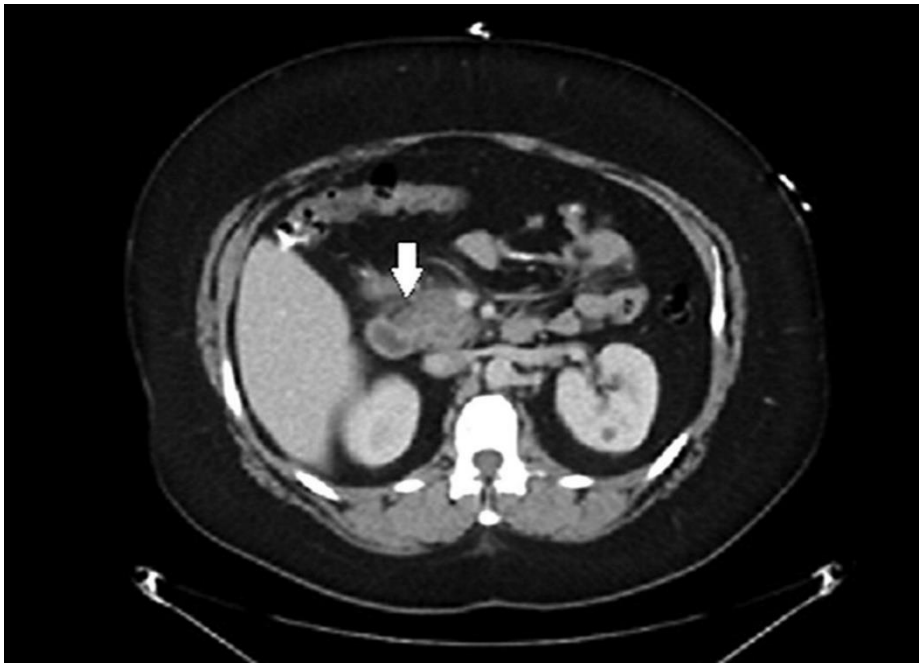

VisualDX 網頁版

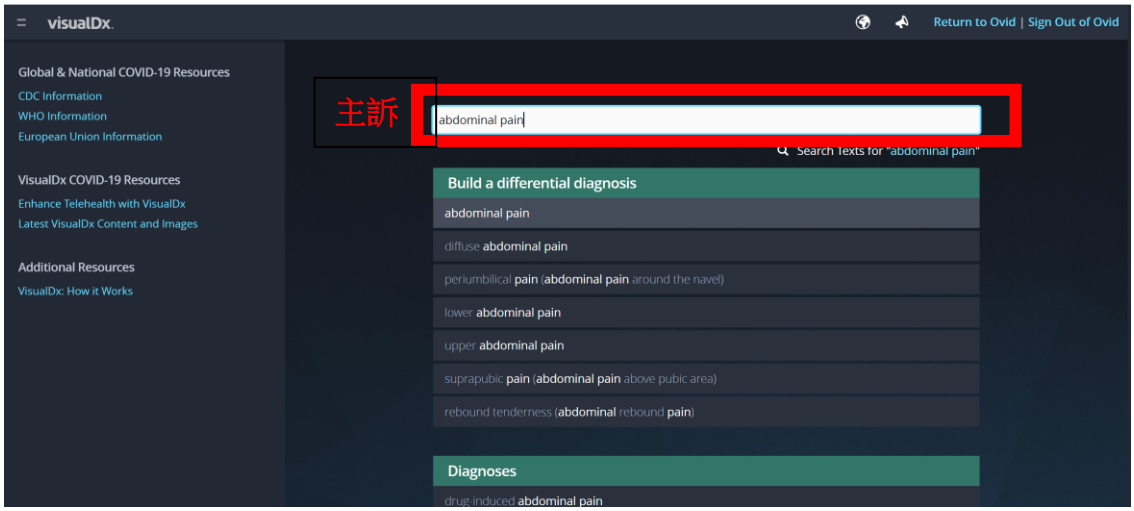

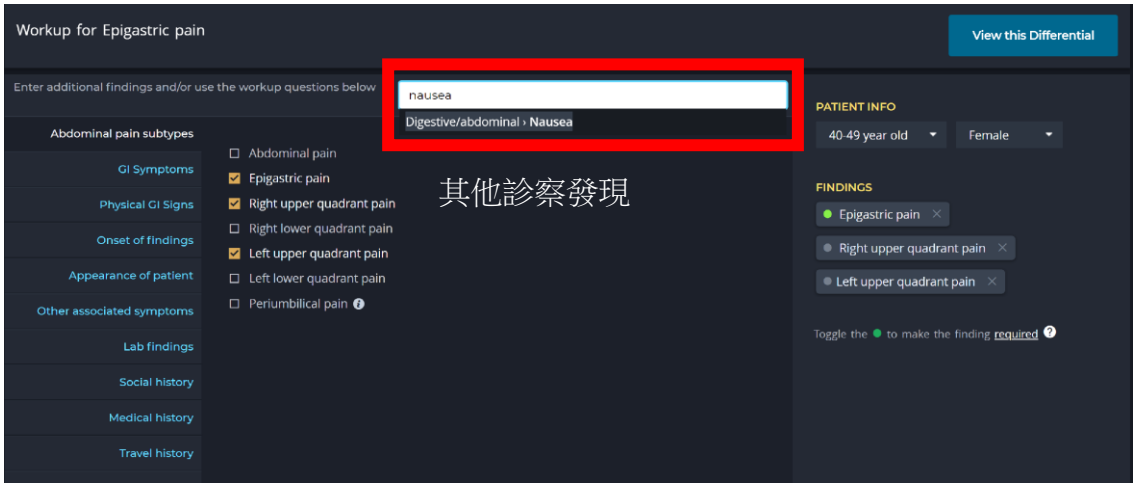

visualDx

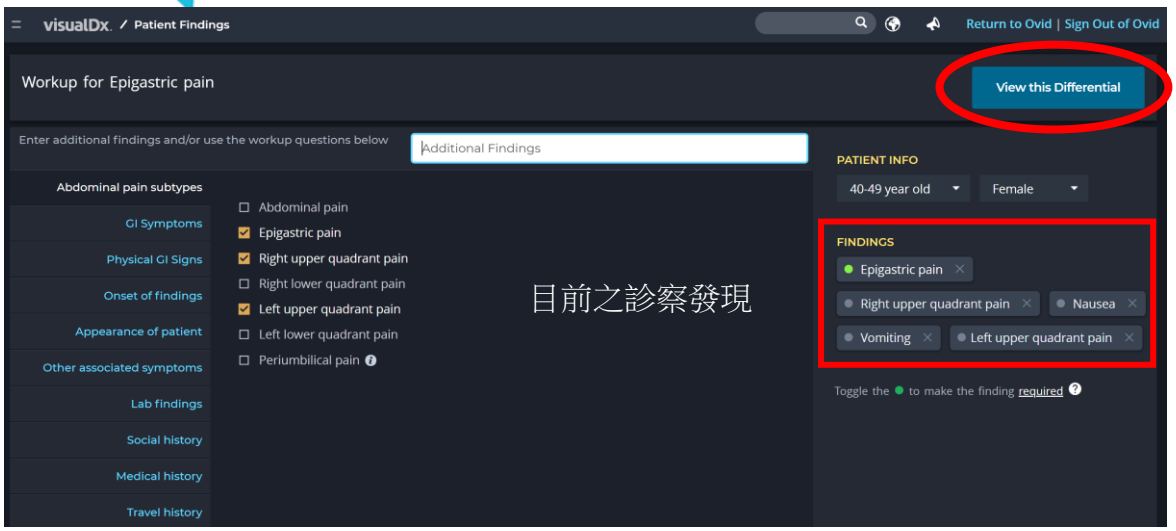
visualDx / Patient Findings
Return to Ovid | Sign Out of Ovid
Workup for Epigastric pain
View this Differential
Enter additional findings and/or use the workup questions below
Additional Findings
Abdominal pain subtypes
GI Symptoms
Physical GI Signs
Onset of findings
Appearance of patient
Other associated symptoms
Lab findings
Social history
Medical history
Travel history
Abdominal pain
Epigastric pain
Right upper quadrant pain
Right lower quadrant pain
Left upper quadrant pain
Left lower quadrant pain
Periumbilical pain
目前之診察發現
PATIENT INFO
40-49 year old
Female
FINDINGS
Epigastric pain
Right upper quadrant pain
Nausea
Vomiting
Left upper quadrant pain
Toggle the to make the finding required

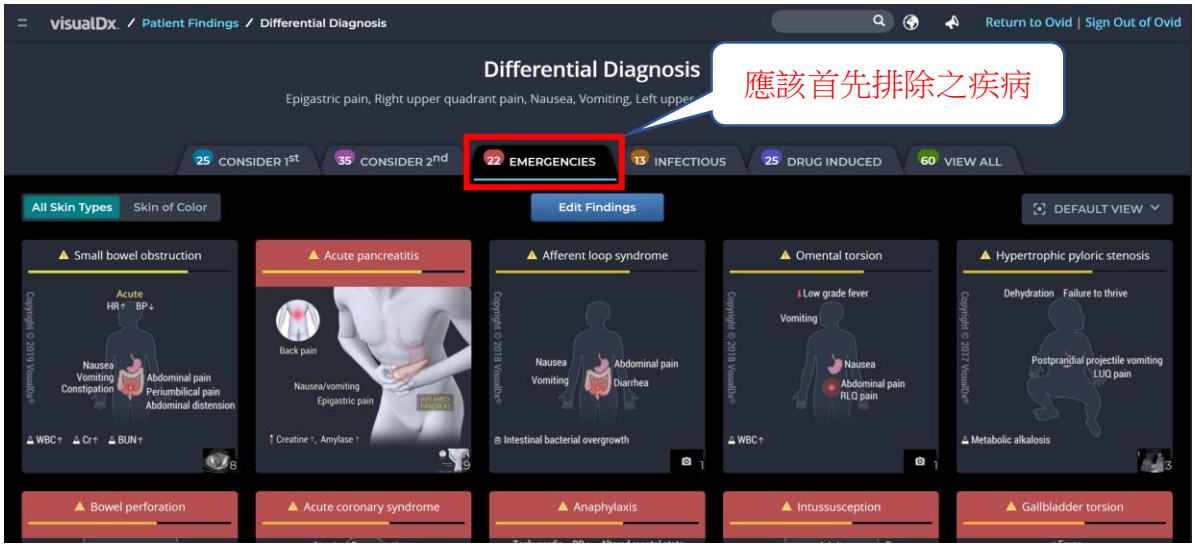
visualDx / Patient Findings / Differential Diagnosis
Return to Ovid | Sign Out of Ovid
Differential Diagnosis
Epigastric pain, Right upper quadrant pain, Nausea, Vomiting, Left upper
應該首先排除之疾病
25 CONSIDER 1st
35 CONSIDER 2nd
22 EMERGENCIES
13 INFECTIOUS
25 DRUG INDUCED
60 VIEW ALL
All Skin Types
Skin of Color
Edit Findings
DEFAULT VIEW
Small bowel obstruction
Acute pancreatitis
Afferent loop syndrome
Omental torsion
Hypertrophic pyloric stenosis
Bowel perforation
Acute coronary syndrome
Anaphylaxis
Intussusception
Gallbladder torsion

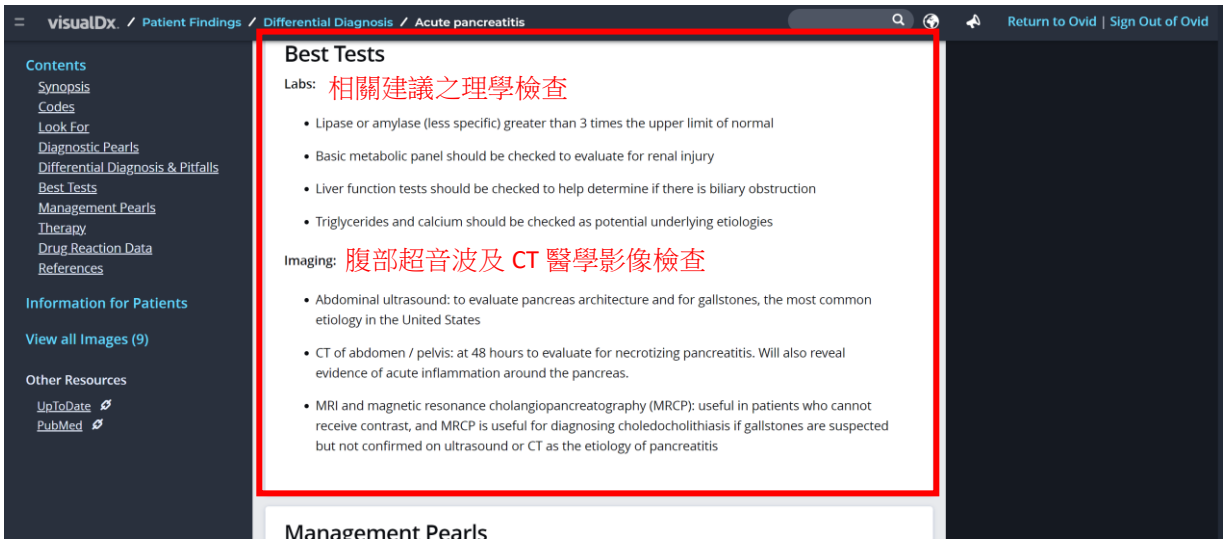
visualDx / Patient Findings / Differential Diagnosis / Acute pancreatitis
Return to Ovid | Sign Out of Ovid
Contents
Synopsis
Codes
Look For
Diagnostic Pearls
Differential Diagnosis & Pitfalls
Best Tests
Management Pearls
Therapy
Drug Reaction Data
References
Information for Patients
View all Images (9)
Other Resources
UpToDate
PubMed
Best Tests
Labs: 相關建議之理學檢查
Lipase or amylase (less specific) greater than 3 times the upper limit of normal
Basic metabolic panel should be checked to evaluate for renal injury
Liver function tests should be checked to help determine if there is biliary obstruction
Triglycerides and calcium should be checked as potential underlying etiologies
Imaging: 腹部超音波及 CT 醫學影像檢查
Abdominal ultrasound: to evaluate pancreas architecture and for gallstones, the most common etiology in the United States
CT of abdomen / pelvis: at 48 hours to evaluate for necrotizing pancreatitis. Will also reveal evidence of acute inflammation around the pancreas.
MRI and magnetic resonance cholangiopancreatography (MRCP): useful in patients who cannot receive contrast, and MRCP is useful for diagnosing choledocholithiasis if gallstones are suspected but not confirmed on ultrasound or CT as the etiology of pancreatitis
Management Pearls

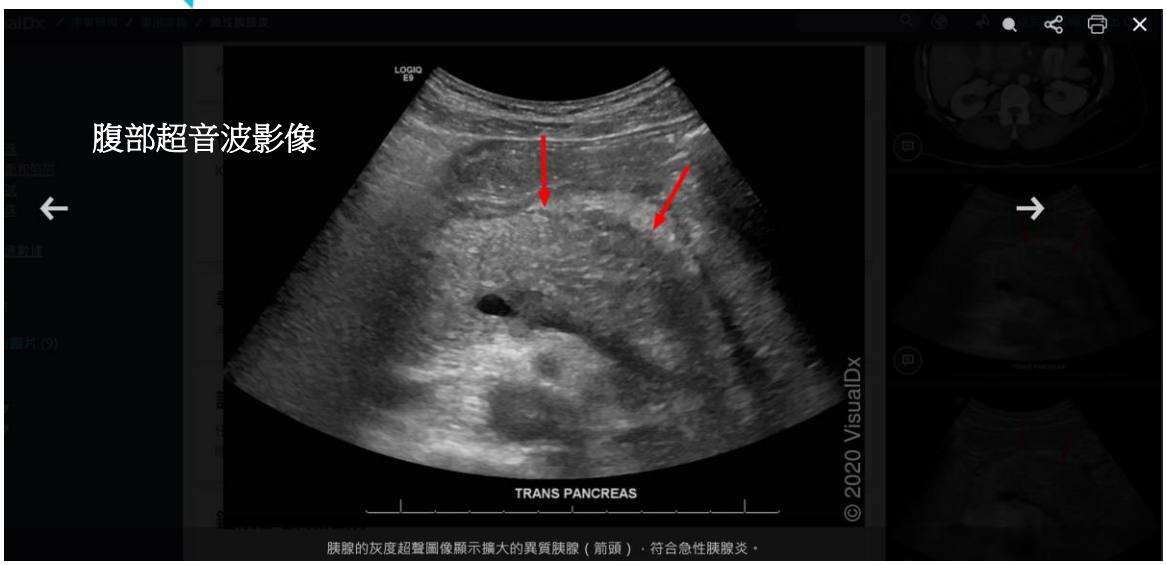

胰腺的灰度超聲圖像顯示擴大的異質胰腺（箭頭），符合急性胰腺炎。

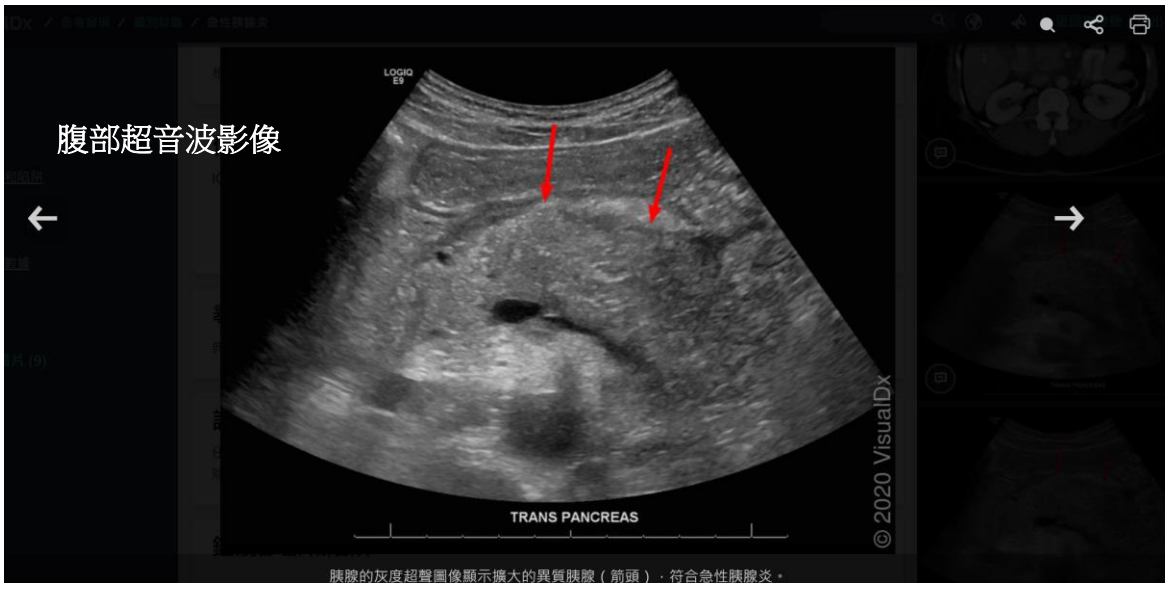

胰腺的灰度超聲圖像顯示擴大的異質胰腺（箭頭），符合急性胰腺炎。

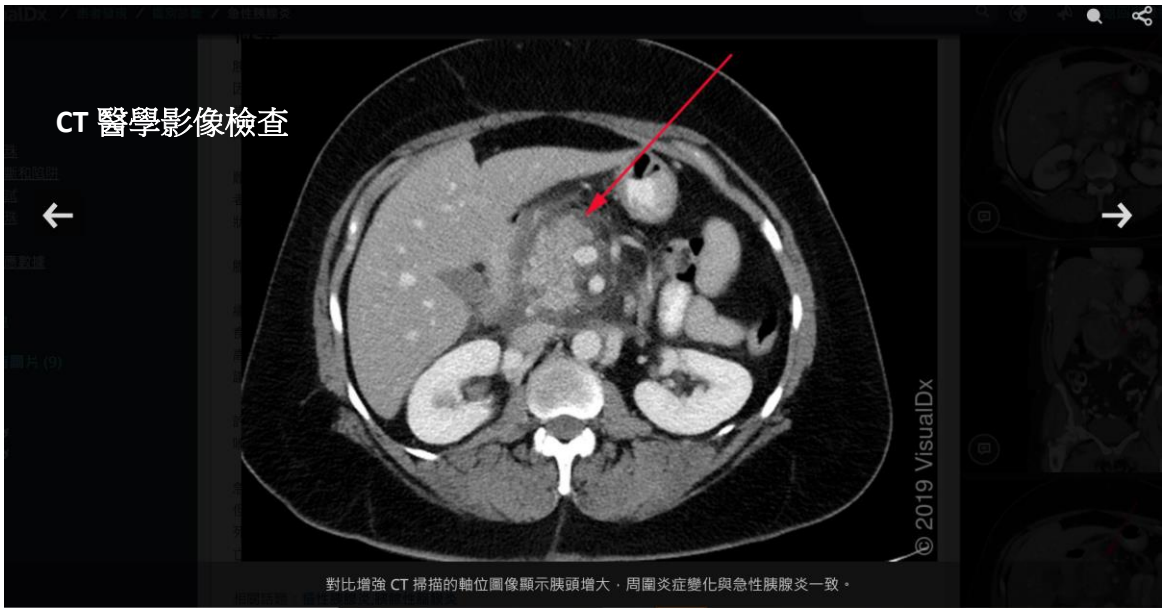

對比增強 CT 掃描的軸位圖像顯示胰頭增大，周圍炎症變化與急性胰腺炎一致。

VisualDX APP 版

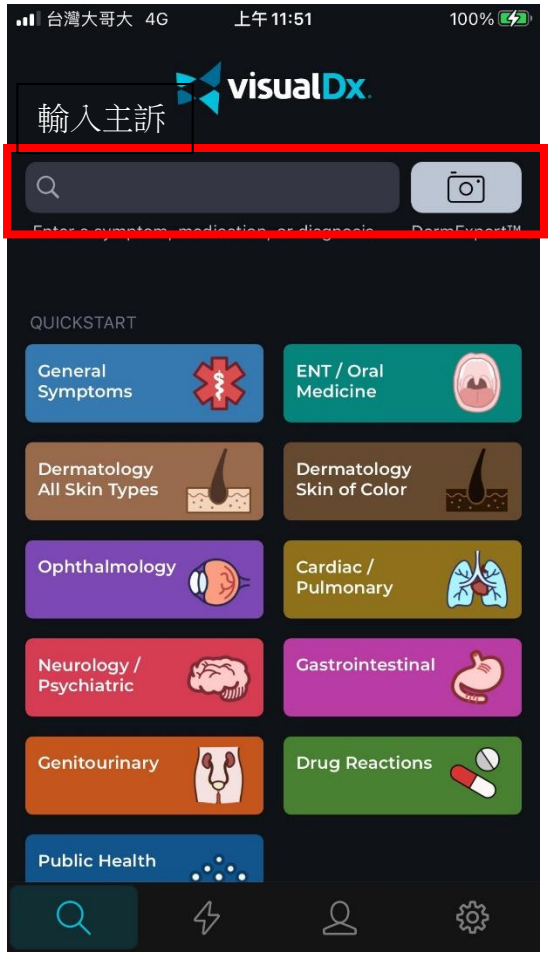

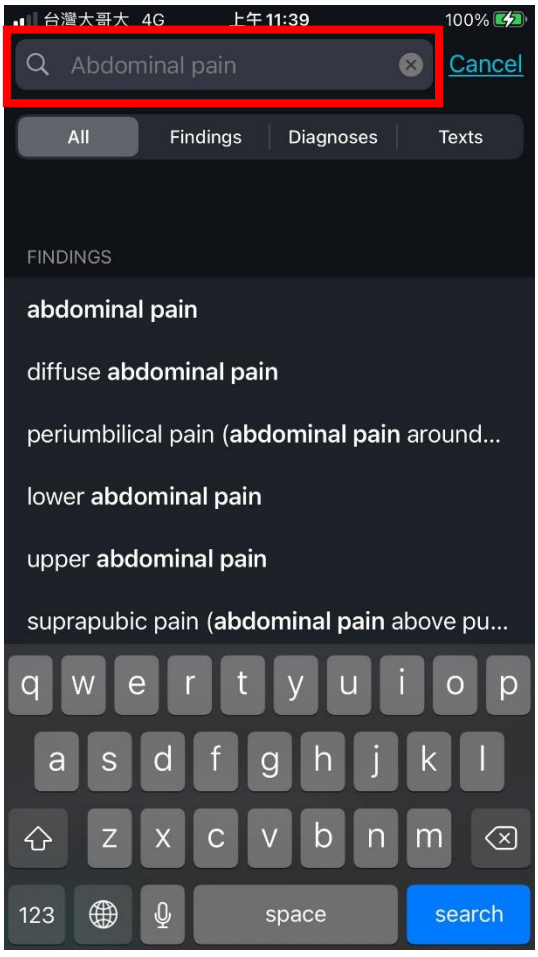

visualDx

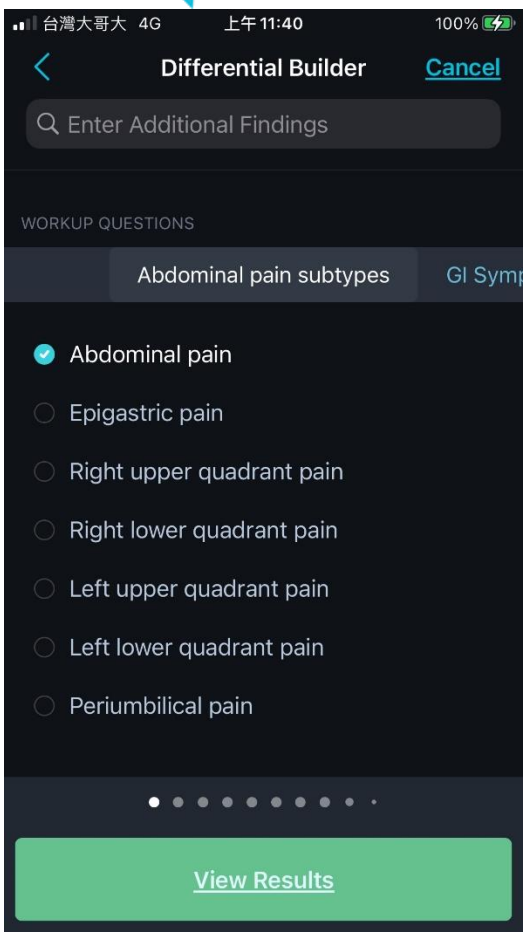
台灣大哥大 4G 上午 11:40 100%
Differential Builder
Cancel
Enter Additional Findings
WORKUP QUESTIONS
Abdominal pain subtypes
GI Symp
Abdominal pain
Epigastric pain
Right upper quadrant pain
Right lower quadrant pain
Left upper quadrant pain
Left lower quadrant pain
Periumbilical pain
View Results

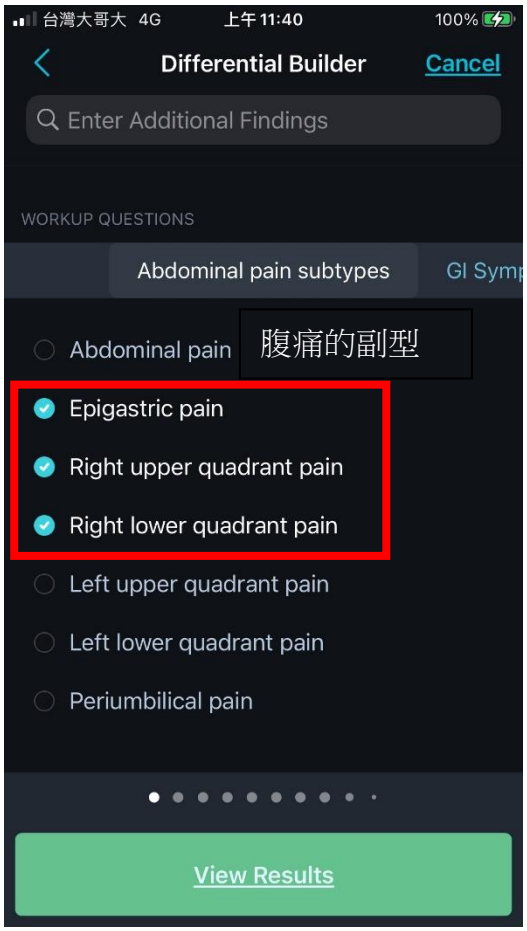
台灣大哥大 4G 上午 11:40 100%
Differential Builder
Cancel
Enter Additional Findings
WORKUP QUESTIONS
Abdominal pain subtypes
GI Symp
Abdominal pain
腹痛的副型
Epigastric pain
Right upper quadrant pain
Right lower quadrant pain
Left upper quadrant pain
Left lower quadrant pain
Periumbilical pain
View Results

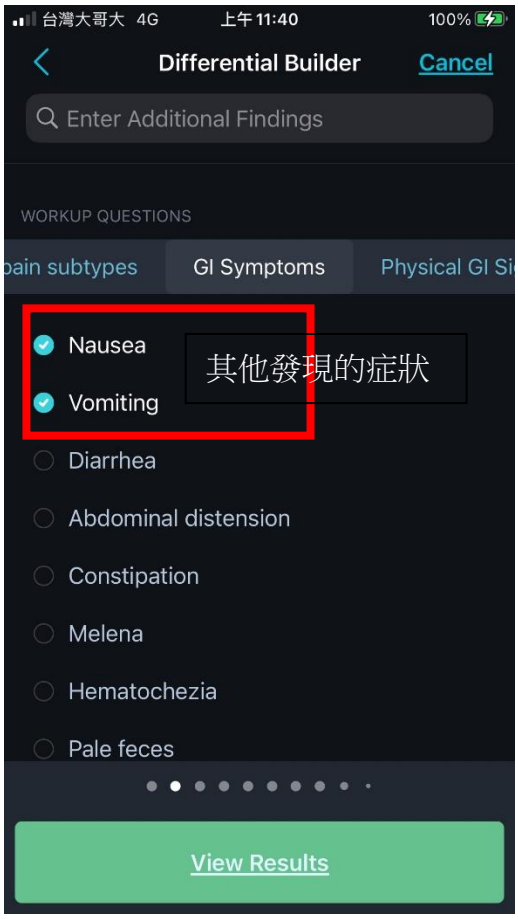
台灣大哥大 4G 上午 11:40 100%
Differential Builder
Cancel
Enter Additional Findings
WORKUP QUESTIONS
pain subtypes
GI Symptoms
Physical GI Si
Nausea
Vomiting
其他發現的症狀
Diarrhea
Abdominal distension
Constipation
Melena
Hematochezia
Pale feces
View Results

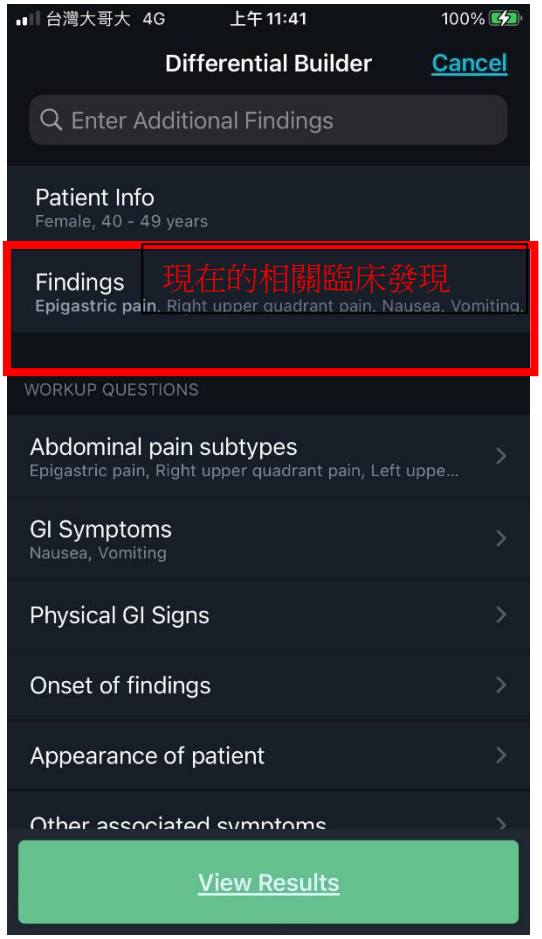
台灣大哥大 4G 上午 11:41 100%
Differential Builder
Cancel
Enter Additional Findings
Patient Info
Female, 40 - 49 years
Findings
現在的相關臨床發現
Epigastric pain, Right upper quadrant pain, Nausea, Vomiting
WORKUP QUESTIONS
Abdominal pain subtypes
Epigastric pain, Right upper quadrant pain, Left uppe...
GI Symptoms
Nausea, Vomiting
Physical GI Signs
Onset of findings
Appearance of patient
View Results

visualDx

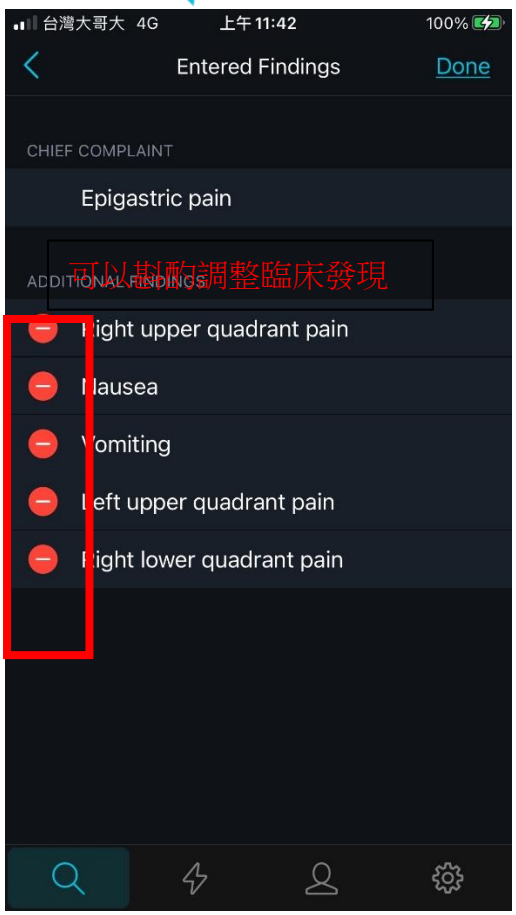
台灣大哥大 4G 上午 11:42 100%
Entered Findings
Done
CHIEF COMPLAINT
Epigastric pain
可以斟酌調整臨床發現
ADDITIONAL FINDINGS
Right upper quadrant pain
Nausea
Vomiting
Left upper quadrant pain
Right lower quadrant pain

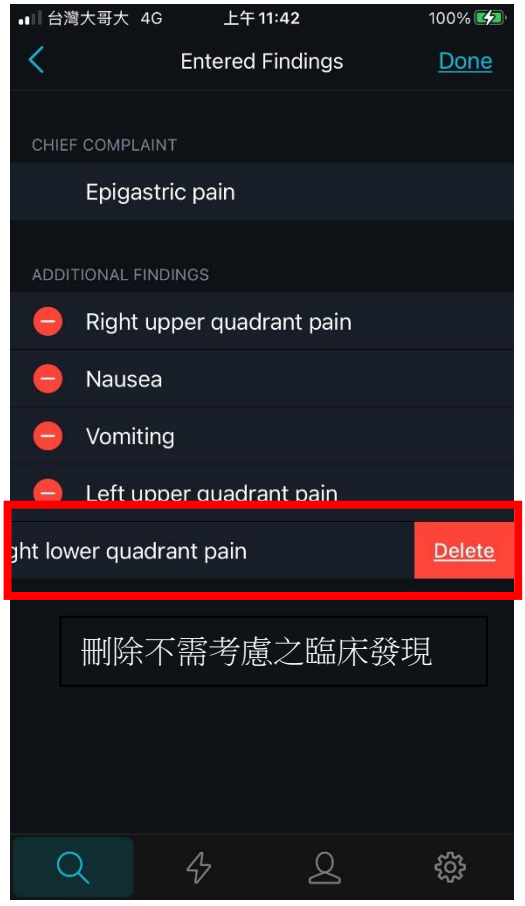
台灣大哥大 4G 上午 11:42 100%
Entered Findings
Done
CHIEF COMPLAINT
Epigastric pain
ADDITIONAL FINDINGS
Right upper quadrant pain
Nausea
Vomiting
Left upper quadrant pain
ght lower quadrant pain
Delete
刪除不需考慮之臨床發現

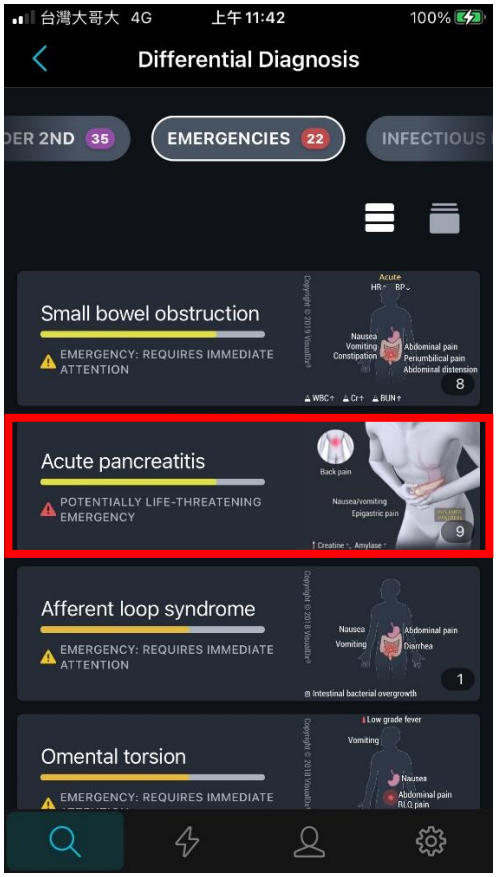
台灣大哥大 4G 上午 11:42 100%
Differential Diagnosis
ER 2ND 35
EMERGENCIES 22
INFECTIOUS
Small bowel obstruction
EMERGENCY: REQUIRES IMMEDIATE ATTENTION
Acute pancreatitis
POTENTIALLY LIFE-THREATENING EMERGENCY
Afferent loop syndrome
EMERGENCY: REQUIRES IMMEDIATE ATTENTION
Omental torsion
EMERGENCY: REQUIRES IMMEDIATE

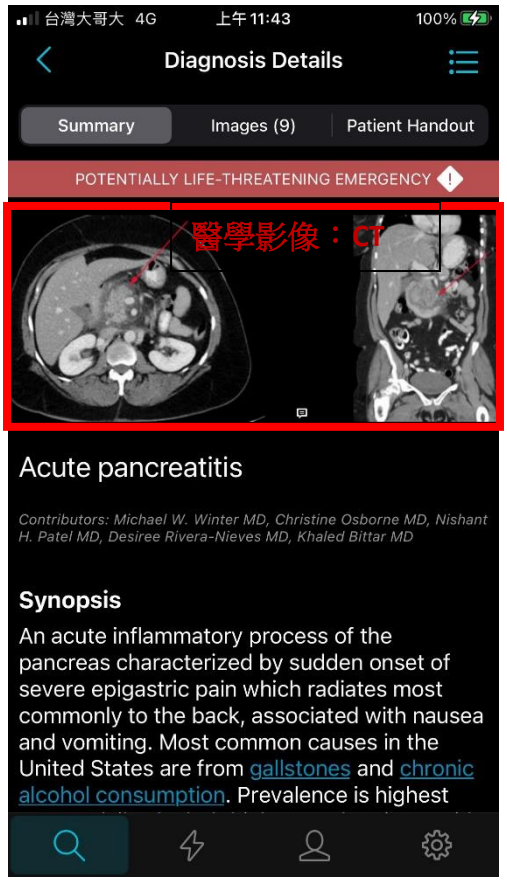
台灣大哥大 4G 上午 11:43 100%
Diagnosis Details
Summary
Images (9)
Patient Handout
POTENTIALLY LIFE-THREATENING EMERGENCY
醫學影像：CT
Acute pancreatitis
Contributors: Michael W. Winter MD, Christine Osborne MD, Nishant H. Patel MD, Desiree Rivera-Nieves MD, Khaled Bittar MD
Synopsis
An acute inflammatory process of the pancreas characterized by sudden onset of severe epigastric pain which radiates most commonly to the back, associated with nausea and vomiting. Most common causes in the United States are from gallstones and chronic alcohol consumption. Prevalence is highest

台灣大哥大 4G 上午 11:43 100%
Diagnosis Details
Summary
Images (9)
Patient Handout
POTENTIALLY LIFE-THREATENING EMERGENCY
Best Tests
建議確認之理學檢查
Labs:
• Lipase or amylase (less specific) greater than 3 times the upper limit of normal
• Basic metabolic panel should be checked to evaluate for renal injury
• Liver function tests should be checked to help determine if there is biliary obstruction
• Triglycerides and calcium should be checked as potential underlying etiologies
Imaging:
• Abdominal ultrasound: to evaluate pancreas architecture and for gallstones, the most common etiology in the United States
• CT of abdomen / pelvis: at 48 hours to evaluate for necrotizing pancreatitis. Will also reveal evidence of acute inflammation around the pancreas.
• MRI and magnetic resonance cholangiopancreatography (MRCP):

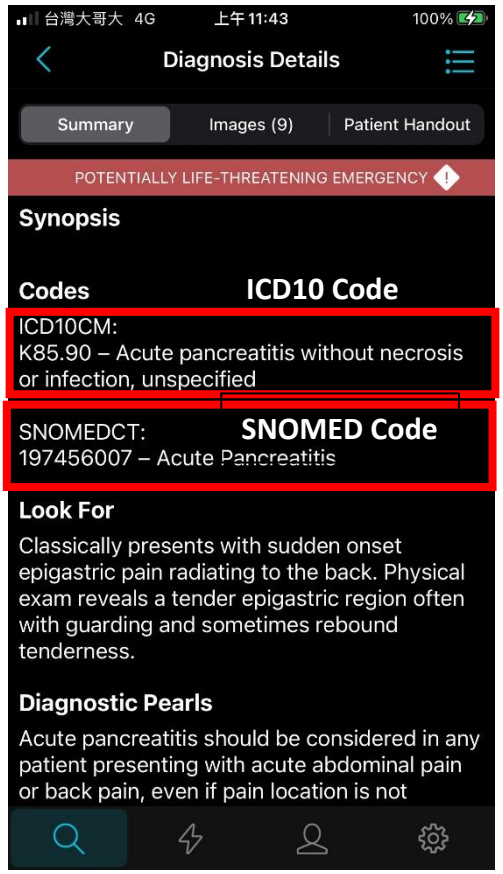
台灣大哥大 4G 上午 11:43 100%
Diagnosis Details
Summary
Images (9)
Patient Handout
POTENTIALLY LIFE-THREATENING EMERGENCY
Synopsis
Codes
ICD10 Code
ICD10CM:
K85.90 – Acute pancreatitis without necrosis or infection, unspecified
SNOMEDCT:
SNOMED Code
197456007 – Acute Pancreatitis
Look For
Classically presents with sudden onset epigastric pain radiating to the back. Physical exam reveals a tender epigastric region often with guarding and sometimes rebound tenderness.
Diagnostic Pearls
Acute pancreatitis should be considered in any patient presenting with acute abdominal pain or back pain, even if pain location is not

台灣大哥大 4G 上午 11:44 100%
Diagnosis Details
Summary
Images (9)
Patient Handout
POTENTIALLY LIFE-THREATENING EMERGENCY
Management Pearls
建議處置
Therapy
With the exception of ERCP for suspected gallstone pancreatitis with concurrent cholangitis, supportive care and aggressive intravenous fluid resuscitation (~200-500 mL/hr per 24 hours) is the mainstay of treatment for acute pancreatitis. Pancreatitis can induce a severe systemic inflammatory response, so upfront aggressive intravenous fluids, pain control (often with intravenous narcotics), and initial bowel rest are critical to early treatment. Resources for opioid prescribing guidelines, as well as nonopioid alternatives, can be found here. Patients with pancreatitis will often have fevers, but antibiotics are not necessary in most instances unless an infection is confirmed.
At 48 hours after beginning treatment, if there has been no marked clinical improvement, a CT of the abdomen / pelvis can be obtained to

DermExpert 模組：

VisualDx 彙整了清晰的皮膚病癥醫學影像圖庫、結合深厚的知識庫及機器學習機制，以協助提供全科醫生皮膚表徵識別。該系統使用人工智慧及機器學習來分析相關病癥以協助疾病之初步鑑別，然後以簡潔的對話介面，協助醫療人員快速進行鑑別診斷。
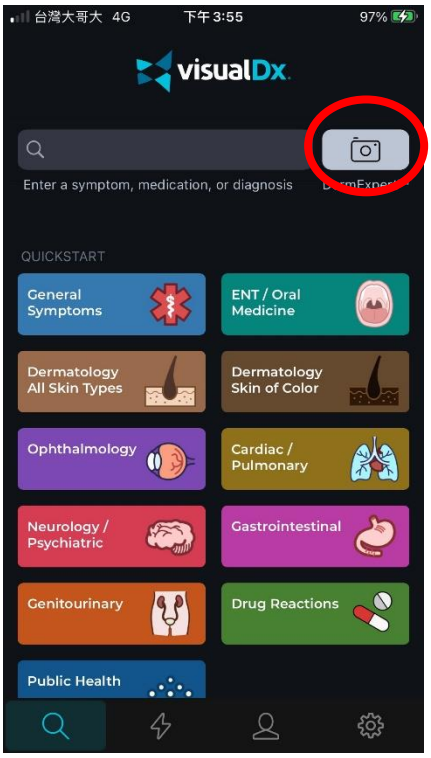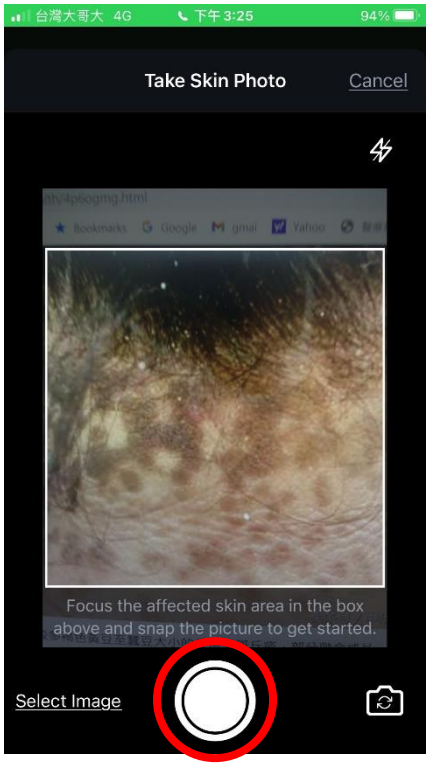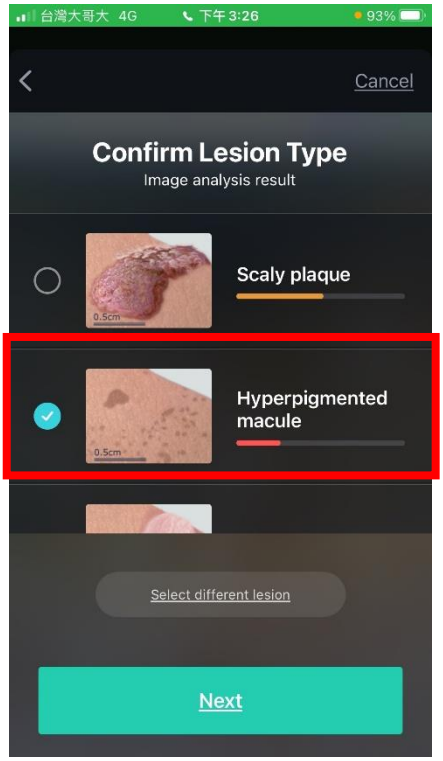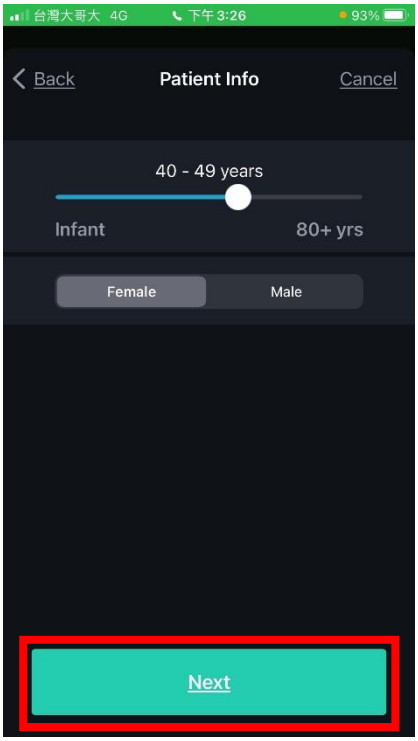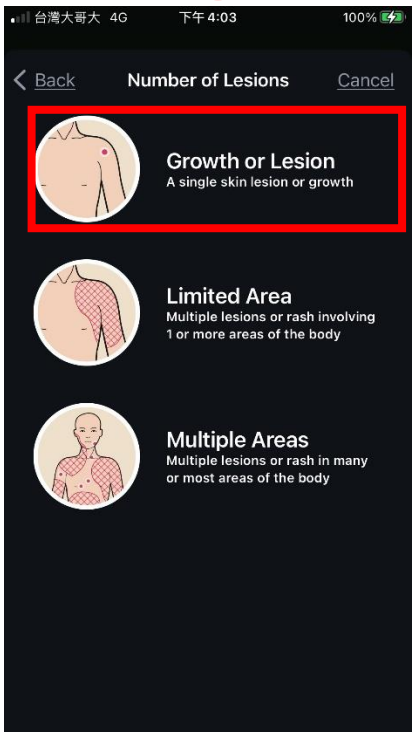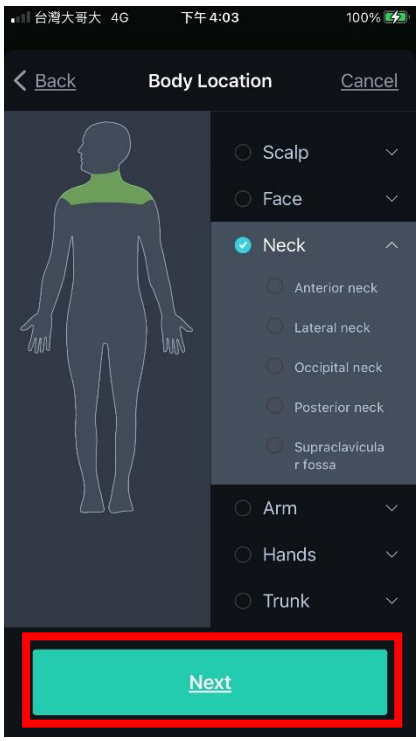
我們關心患者隱私，因此我們符合 DermExpert HIPAA 規則。使用 DermExpert 為患者拍照並不會將傳輸圖像保存到設備中。